

THE CENTRAL NERVOUS SYSTEM IN TERATOPHTHALMIC AND TERATOMORPHIC FORMS OF  
*PLANARIA DOROTOCEPHALA*.

C. M. CHILD AND E. V. M. MCKIE.

The study of the nervous system in the teratophthalmic and teratomorphic forms of *Planaria dorotocephala* was undertaken by the junior author of this paper at the senior author's suggestion. The results of this study were accepted as a thesis for the Master's degree by the Department of Zoölogy of the University of Chicago. Since the results of the work are of considerable interest and since Miss McKie was prevented by various circumstances from preparing the paper for publication, the senior author has undertaken, at her express request, to revise her manuscript for publication and to add some figures from her slides; he has also added a section on the various methods by which the teratophthalmic and teratomorphic forms have been produced and has extended somewhat the scope of the discussion of the results.

The primary object of the work was to determine the general form and the degree of development of the cephalic part of the central nervous system in these abnormal forms as compared with normal animals. The observations concern chiefly the teratomorphic forms since these represent a more extreme departure from the normal type and afford more definite and striking results.

The animals for sectioning were anesthetized with weak alcohol before fixation in hot Gilson's fluid or sublimate. Sections were cut ten micra in thickness. Frontal and sagittal as well as transverse sections were made, but all the figures are drawn from transverse sections since these show the essential features most clearly.

All figures of sections were drawn to the same scale with the camera. They are designed to show, first the general form of the nervous system and second, the general relations between fiber tracts and cells. The cells are represented merely by small

circles or ovals and the fiber tracts are filled in with dots, except where a distinct commissure or nerve is concerned; there the direction of the fibers is indicated. Non-nervous structures are not shown except in the case of the alimentary tract, which is diagrammatically indicated where it is present in the sections figured.

## I. THE EXPERIMENTAL PRODUCTION OF TERATOPHTHALMIC AND TERATOMORPHIC FORMS.

The senior author has given the names "teratophthalmic" and "teratomorphic" to certain types of head which appear under certain conditions in the regulation of pieces of *Planaria*. The teratophthalmic head (Child, '11a, pp. 278-9; '11c) is one in which the eyes show some departure from the usual structure or arrangement, but the head is otherwise normal in form. The teratophthalmic forms may be divided into several groups according to the character of the eyes, for these may be "abnormal" in position, size or number or the pigment cups may show the most various degrees of fusion (*e. g.*, Fig. 6 below).

The teratomorphic heads (Child, '11c) represent a more extreme departure from the norm. In these the abnormalities involve not only the eyes but the shape of the head and the position of the auricles. The teratomorphic head usually possesses a single median eye and the auricular sense organs appear on the front of the head, either separate (Figs. 10 and 16) or more or less completely fused (Figs. 19 and 23). In the senior author's earlier work on *Planaria* the teratomorphic heads were not separated from the teratophthalmic (Child, '11a), but as the degree of experimental control in the production of these forms increased it became desirable to set these peculiar forms apart as a distinct group and to give them a name.

It is possible, as the senior author has shown in various papers (Child, '11a, '11c, '11d), to control experimentally by a number of different methods the production of these forms. In general they are the result of conditions which decrease the rate of the dynamic processes below a certain level determined by existing conditions which is necessary for the production of normal animals. With the proper experimental conditions they can be

produced from any region of the planarian body and from pieces of any size above a certain minimum, which varies with region of the body, physiological condition, age, nutrition and external conditions. A regional factor does, however, exist (Child, '11a): in pieces of a given length the more posterior the level within a single zoöid, the greater the frequency of the abnormal forms.

Thus far it has been possible to control experimentally the production of teratophthalmic and teratomorphic as well as anophthalmic and headless forms (Child, '11c) in the following ways: first, under standard conditions of temperature, nutrition, etc., pieces above a certain length with anterior ends at a certain level of the body will produce normal wholes, shorter pieces will produce teratophthalmic forms and still shorter pieces teratomorphic, anophthalmic and headless forms as the length decreases. Second, in pieces of a given length from a given region, under uniform conditions of temperature, nutrition, etc., stimulation to motor activity increases the frequency of normal animals, while lack of stimulation increases the frequency of teratophthalmic, teratomorphic, anophthalmic and headless forms. Third, in pieces of a given length from a given region of animals of the same size the frequency of abnormal and normal forms varies with differences in physiological age (Child, '11b) and with differences in nutrition. Fourth, in pieces of a given length from a given region of animals of the same size and as nearly as possible in the same physiological condition a variety of external factors such as low temperature, metabolic products in the water, dilute alcohol, ether, chloretone, potassium cyanide, etc., will increase the frequency of abnormal forms and it is possible to control to a certain extent the type of abnormal form, both through the length of the piece and the intensity of the experimental factor. On the other hand, the frequency of normal forms in a given set of pieces can be increased by good nutrition, by high temperature and probably also by certain stimulating drugs, though as regards these last the results are complicated by the fact that in many cases the stimulating effect of drugs is of relatively short duration and is followed by a depression.

But whatever may be the results of more extended experiment, the facts already established demonstrate that the normal and

the abnormal forms described represent differences in the dynamic processes which are primarily purely quantitative. The temperature experiments illustrate this point very clearly. In a given set of pieces higher temperatures increase the frequency of normal, lower temperatures that of abnormal forms. The effect of the anesthetics and the other external factors mentioned above is probably also primarily quantitative.

In these cases then different morphological characteristics appear as the result of primarily quantitative changes in the dynamic processes in the organism. This fact is of considerable theoretical importance, since it can mean nothing else than that form, structure, localization, number and even presence or absence of parts may be determined by purely quantitative changes in external factors, *i. e.*, by changes which alter primarily the rate and not the character of the dynamic processes.

Certain external characteristics of the head region of the abnormal forms, *viz.*, the position and number of the eyes and auricles, indicate that the cephalic ganglia of these forms must show considerable departures from the norm. The question as to how the form and structure of the central nervous system may be altered by these quantitative changes in the dynamic processes is one of interest from various points of view. The data presented below give a partial answer to this question and so form a contribution to our knowledge of the dynamics of morphogenesis.

The method used for obtaining the teratophthalmic and teratomorphic forms described in this paper was that of cutting pieces of a certain length, determined by previous experiments of the senior author, from the middle region of the body of large, well fed worms and allowing them to undergo regulation at about 20° C. This method was used merely because it is the simplest. Teratophthalmic and teratomorphic heads develop on pieces of greater length from the middle region of the body, *i. e.*, the posterior region of the first zoöid (Child, '11a, '11e) than from any other region. This makes it possible to use relatively long pieces and the preparation and handling of the material is therefore less difficult. Of course the abnormal heads can be obtained from still longer pieces if regulation occurs at low temperatures,

but the length of time necessary for regulation in such cases is a disadvantage. Abnormal heads produced by the action of anesthetics and by various other conditions were not included within the scope of the present investigation. It is not improbable that comparison of the heads produced by different conditions will show more or less characteristic differences in the nervous system.

In all cases described the pieces were kept for at least two weeks after section. After this length of time the new head is well developed and those cases in which the teratomorphic head does not remain teratomorphic but redifferentiates into a head of normal shape have already undergone this further regulation or show unmistakable indications of it. The teratomorphic heads which persist as such for two weeks at 20° C. almost never show any further changes.

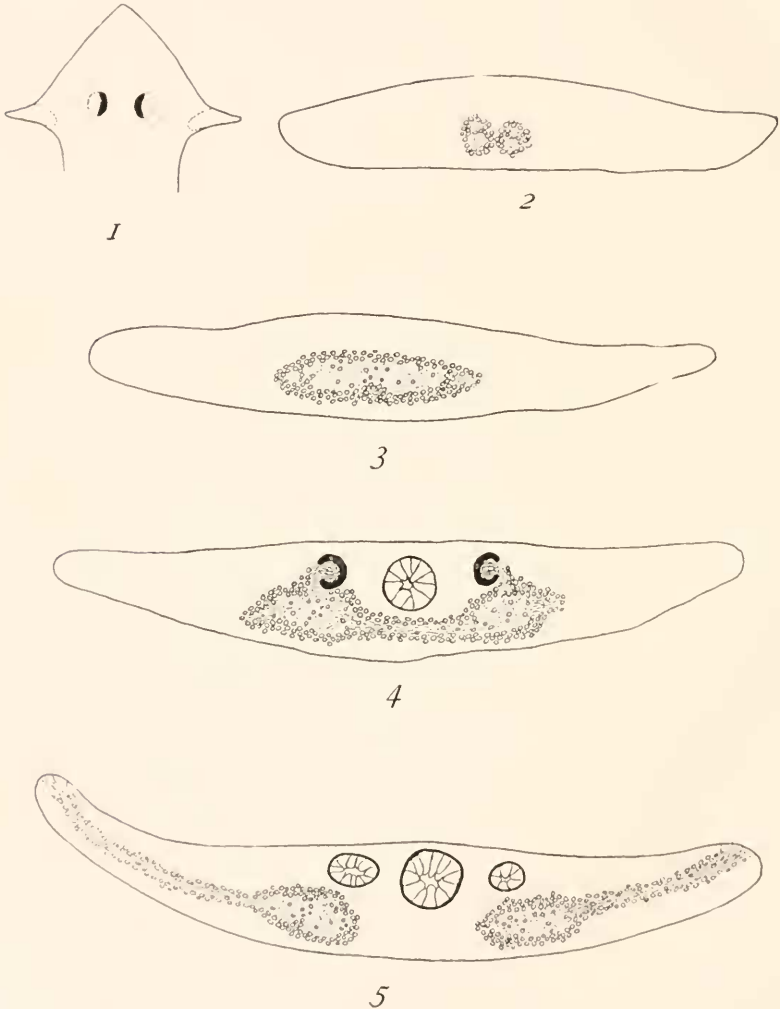
## II. THE HEAD OF THE NORMAL ANIMAL.

The form and the chief external features of the normal head of *Planaria dorotocephala* are shown in Fig. 1. The unpigmented areas of the eyes and the very slightly pigmented sensory regions of the auricles are indicated by dotted lines. Except for these the dorsal surface of the head is usually rather deeply and uniformly pigmented. From the ventral surface the outlines of the cephalic ganglia and nerve cords are indistinctly visible in the living animal.

Figures 2-5 show transverse sections of the nervous system at different levels of the head region. Fig. 2 is from a level about half way between the eyes and the tip of the head and shows four nerves extending to the anterior head region. Further anteriorly these nerves break up and become less distinct as they are distributed. Fig. 3 shows the ganglia at about one fourth of the distance from the eyes to the tip. They consist of fiber tracts including a few cells and surrounded by many others. At this level the chief fiber tract shows indications of a beginning separation into right and left halves. On each side of the chief tract is a small tract separated from it by cells: these two small tracts are cross sections of nerves which pass to the anterior regions of the head.

Figure 4 shows the ganglia at the level of the eyes. The two

masses lie some distance apart and are connected by commissures. The pigment cups of the eyes open laterally and the optic nerves pass in a dorso-ventral direction. Between the eyes the median anterior branch of the alimentary tract appears.



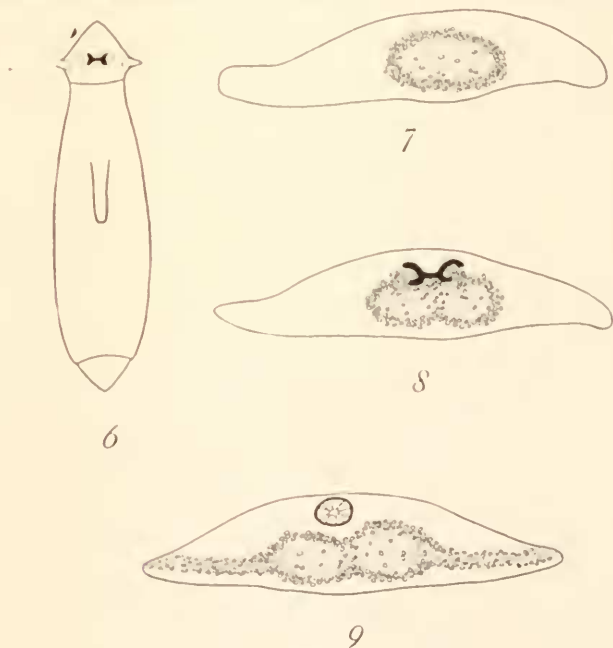
FIGS. 1-5.

Figure 5 is from a section at the level of the auricles. Here there is no distinct commissure between the ganglionic masses. It is quite possible, however, that they are not entirely discon-

nected as they appear in the figure; some nerve fibers may extend across the space between them. The nerves passing to the auricles appear in the section and the alimentary tract lies on the dorsal side. Posterior to this level the nervous system consists of the two main nerve cords, each composed of a fiber tract including some cells and surrounded by others and giving rise to nerves and commissures at various levels.

### III. TERATOPHTHALMIC HEADS.

Of the various types of teratophthalmic heads only those which show partial fusion of the optic pigment cups were examined. The forms with unequal or unsymmetrical eyes constitute a somewhat different type of teratophthalmia and require a more extended investigation: moreover, the partial fusions of the eyes



FIGS. 6-9.

lead through all possible stages to the single median eye of the teratomorphic head.

Figure 6 shows the outline of the body and the condition of the eyes in one of the teratophthalmic heads sectioned. The

two optic pigment cups are symmetrically situated but lie closer together than in normal animals and are united by a continuous band of pigment.

In Fig. 7 a transverse section of the nervous system from about the posterior fourth of the preocular region is shown. It consists of a single fiber tract surrounded by cells and without any trace of division into right and left halves. Comparison with Fig. 3 which is from about the same level in the normal animal shows a marked difference in form. Fig. 8 shows the level of the eyes. The difference between this and Fig. 4 from the normal animal is striking. In Fig. 8 the fiber tract is partially divided into right and left halves, but the two parts are close together instead of being widely separated and connected by a long commissure as in Fig. 4. In Fig. 9 a section at the level of the auricles is drawn: much the same differences from the normal (Fig. 5) appear here. The two ganglionic masses are closely connected, while in the normal animal they are widely separated.

The figures from this teratophthalmic head show one other point of interest. The individual from which the sections were made was much smaller than the full grown animal of Figs. 2-5. Figs. 2-5 and 7-9 are drawn to the same scale and comparison shows at once that the ganglia are almost as large in the teratophthalmic as in the normal animal. This is a general characteristic of physiologically younger as compared with older and of smaller as compared with larger animals. In the small young animal the nervous system is always of relatively large size and in small animals which result from the regulation of pieces the same is true, except in the more extreme abnormal types, where the nervous system is often small. Thus as regards the development of the nervous system as well as its rate of metabolism during development (Child, '11*b*) the animal formed by regulation resembles a young animal.

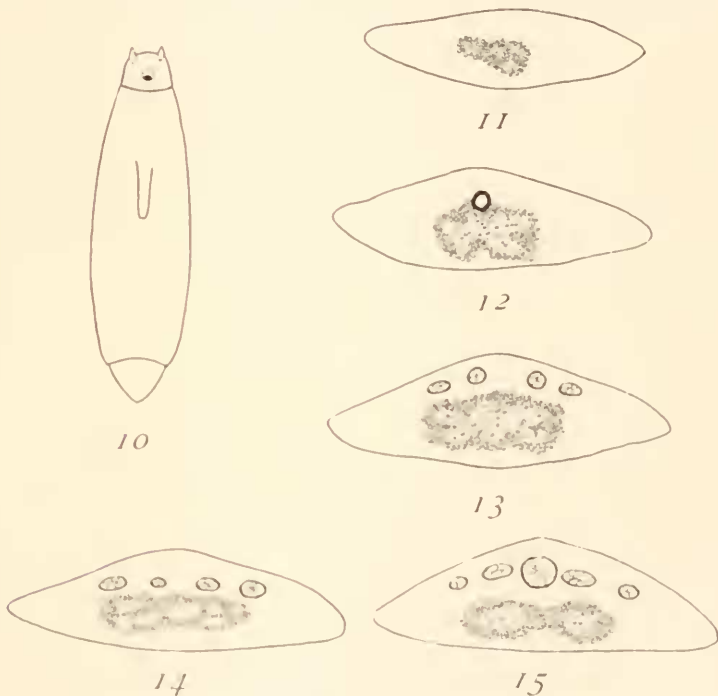
In other teratophthalmic individuals with partially fused eyes the general form of the ganglia was found to be much the same as in the case described and the degree of fusion or separation of the ganglia corresponds rather closely with the degree of fusion or separation of the eyes. In these forms then the eyes serve to some extent as an index of the condition of the nervous system.



## IV. TERATOMORPHIC HEADS.

1. The first case to be described is shown in Fig. 10. Here the auricles appear on the front of the head and extend anteriorly. The anterior margin of the head between them is slightly rounded instead of pointed as in the normal animal. In the median line is a single eye.

Sections of the head region of this animal are shown in Figs. 11-15. The eye is situated almost at the extreme anterior end



FIGS. 10-15.

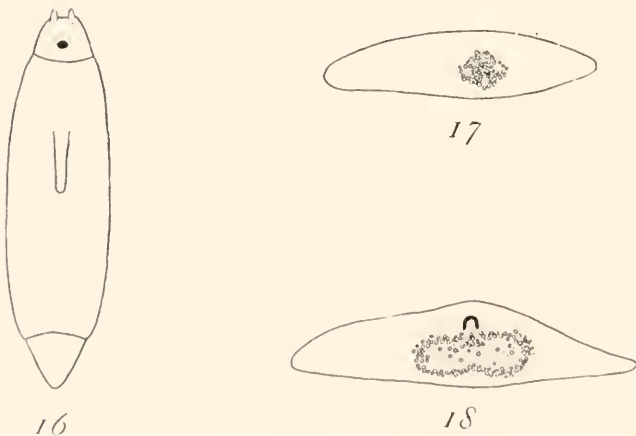
of the ganglionic mass and a few sections anterior to it the nervous system appears as in Fig. 11. Here four fiber tracts surrounded by cells are visible and are evidently nerves to the anterior regions of the head. The conditions at the level of the eye are shown in Fig. 12. The single optic pigment cup opens anteriorly instead of laterally, as the adjoining sections on the slide show, and it is farther from the dorsal surface of the head and more nearly imbedded in the ganglionic mass than in

the normal animal (Fig. 4). The ganglionic mass itself is somewhat irregular in form and shows no trace of a division into symmetrical right and left portions.

Figure 13 shows the condition of the ganglia six sections (sixty micra) posterior to the eye. Here the fiber tracts show indications of a symmetrical arrangement, but this arrangement is widely different from the normal. Three sections farther posteriorly the fiber tracts are still more broken up, as shown in Fig. 14. The level of this section is approximately the posterior end of the anterior new tissue of the regenerated region. Fig. 15 shows a section sixty micra posterior to the level of Fig. 14, *i. e.*, in the old tissue: here the nervous system appears in the usual form of two ganglionic ventral cords, which, however, are much less widely separated than in the normal animal at this level.

2. The animal sectioned is shown in Fig. 16. The head is much like that in Fig. 10, but the auricles are somewhat closer together. A single median eye with a rather large pigment spot is present.

Figures 17 and 18 show sections of the head. Fig. 17 is a



FIGS. 16-18.

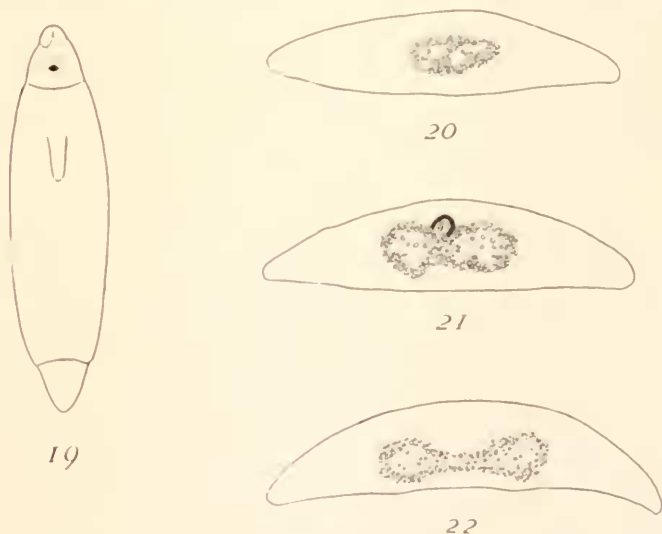
section a short distance anterior to the eyes, about the posterior fourth of the preocular region. Fig. 18 shows the level of the eyes. The single pigment cup appears in the figure to open ventrally, but the opening is actually antero-ventral in direction. The ganglionic mass is distinctly double, *i. e.*, more like the

normal than that of Fig. 12. Two nerves, one from each portion of the ganglionic mass, pass to the optic cup.

Here, as in the preceding case, the eye is situated near the extreme anterior end of the ganglionic region instead of a considerable distance posterior to it as in normal forms. Posterior to the eye the form of the ganglionic mass continues much the same as in Fig. 18 to about the posterior end of the new tissue, where the right and left portions become more distinctly separated with a commissure between them and then pass into the two nerve cords.

In general form the nervous system is much less abnormal in this than in the preceding case. The chief differences from the norm are the anterior position of the eye on the ganglionic mass and the partial fusion of the two ganglia for a considerable distance posterior to the eye.

3. As indicated in Fig. 19, this case shows a somewhat extreme



FIGS. 19-22.

form of teratomorphism. The two auricles are fused at the tip of the head, though the sensory areas are in large part separate. A single median eye is present as in the preceding cases.

Fig. 20 shows a transverse section of the nervous system at the level where the nerves to the front of the head arise; this is about

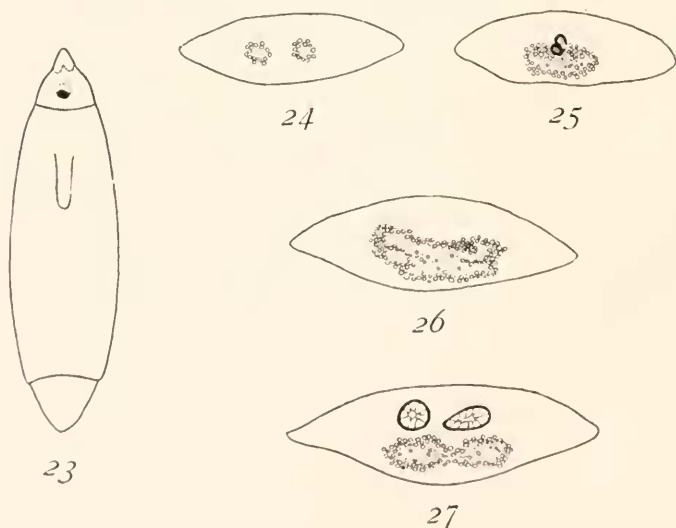
one fifth of the distance from the eyes to the tip of the head. Five fiber tracts unsymmetrically situated are indicated in the section.

In Fig. 21 the level of the eye is shown. The optic pigment cup opens antero-ventrally and toward the left side and is connected by a nerve with the left side only of the ganglionic mass. The latter shows a distinct division into right and left halves.

Near the posterior end of the regenerated region the nervous system possesses the form shown in Fig. 22 and a short distance posterior to this level and in the old tissue the two nerve cords become separate except for an occasional commissure.

In this case the eye, though median in position, evidently belongs to the left half of the ganglionic mass and the nervous system is much less abnormal than in Case 1. As in the other cases, the eye is situated near the extreme anterior end of the ganglion.

4. In this case (Fig. 23) the fusion of the auricles at the front



FIGS. 23-27.

of the head is even more complete than in Case 3, only the bases of the sensory areas being separated. The eye is median and apparently single and the pigment spot is of rather large size. Anterior to the eye the ganglionic mass breaks up almost imme-

diately into two nerves passing to the front of the head (Fig. 24). In Fig. 25 it becomes evident that the apparently single eye is actually double. One of the pigment cups lies slightly anterior and ventral to the other and somewhat to the left of it. The opening of the more posterior and dorsal cup is seen in Fig. 25, while the other pigment cup appears here as a complete circle. Both open antero-ventrally and toward the right. The ganglionic mass is not divided into right and left halves and the optic nerves arise from its median region. Both eyes are far below the dorsal surface of the body and the more ventral one is imbedded in the ganglion.

The double nature of the eye is not apparent in the living animal since the two pigment cups lie so close together and one is almost ventral to the other.

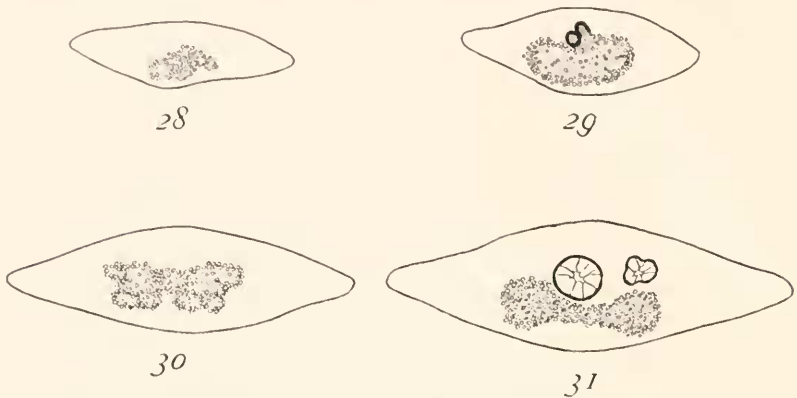
Posterior to the level of the eyes the ganglion is abnormal in form to about the posterior end of the regenerated region. Fig. 26, a section slightly anterior to the boundary between new and old tissue, shows that in general form and arrangement of the fiber tracts the ganglion at this level resembles that of Case 1 (Fig. 13). A little farther posteriorly, in the old tissue, it divides into right and left portions and gives rise to two nerve cords of the usual form, but somewhat nearer together in their anterior region than in normal forms.

5. This case is like Case 4 in external appearance (Fig. 23) and also in the number and arrangement of the eyes, but some differences in the structure of the nervous system exist. Fig. 28 shows the level of origin of nerves to the front of the head, a level slightly anterior to the eyes. In Fig. 29 the eyes are seen to be slightly larger than in the preceding case, but otherwise similar to it. Both open antero-ventrally and toward the right and one lies to the left of, ventral and slightly anterior to the other. The ganglionic mass is single, but larger than in Case 4 at this level (Figs. 29 and 25) and the optic nerves arise from it somewhat to the right of the middle.

Posterior to the eyes the ganglion soon shows distinct right and left halves but these are abnormal in shape and each is broken up into a number of more or less distinct fiber tracts, which, however, are apparently symmetrically arranged in the

right and left halves (Fig. 30). This peculiar arrangement continues to about the posterior end of the regenerated region and then changes into the form shown in Fig. 31: posterior to this the two ventral cords appear in the usual form.

These five cases give some idea of the variations in structure of the eyes and the nervous system in the teratomorphic forms. A



FIGS. 28-31.

more extended investigation of these forms will undoubtedly show other variations in structure and examination of anophthalmic and headless forms will add still further data of interest.

## V. DISCUSSION.

In all of the cases described, both the teratophthalmic and the teratomorphic forms, the most conspicuous difference in the nervous system as compared with the normal forms is the more or less complete fusion in the median line of the two portions of the ganglionic mass, or more correctly, their incomplete separation.

It is evident that to some extent the condition of the eyes or eye is an index of the condition of the nervous system. The parallelism is, however, not complete: in Case 1 (Figs. 10-15), for example, the nervous system is much more abnormal than in Cases 2 (Figs. 16-18) and 3 (Figs. 19-22), though all three possess a single median eye.

Moreover, the degree of fusion of the auricles does not correspond exactly to the degree of fusion of the ganglia in all cases.

In Case 1 where the auricles are a considerable distance apart (Fig. 10) the fusion of the ganglia (Figs. 11-15) is more complete and their structure is more abnormal than in Cases 2 (Figs. 16-18) and 3 (Figs. 19-22), where the auricles are nearer together. In Cases 4 and 5, where two eyes develop close together, far from the surface and in abnormal relations to each other and where the auricles are partially fused, the ganglionic region is highly abnormal.

When, however, we compare the teratophthalmic with the teratomorphic forms it is evident that a general parallelism between the external features of the head and the condition of the nervous system does exist. So far as the observations go at present, the nervous system is always more abnormal in the teratomorphic forms than in the teratophthalmic forms with partially fused eyes.

As regards the eyes themselves certain points are of interest. In the normal and partially fused eyes the pigment cups open laterally, while in the teratomorphic forms they open anteriorly or antero-ventrally. Moreover, the eyes are usually farther from the dorsal surface of the head in the teratomorphic forms than in others.

The single eye of the teratomorphic head may be connected with both sides of the ganglionic mass (Fig. 18) or with only one (Fig. 21) and in case two optic cups arise in the teratomorphic head (Figs. 25 and 29) they may both be connected with the same part of the ganglion.

The position of the eyes or eye on the ganglion may differ more or less widely in the normal and abnormal forms. In the normal animal (Figs. 1-5) the eyes lie dorsal to the posterior region of the ganglion, which divides a short distance behind them into the two nerve cords. In the teratophthalmic forms with partially fused eyes a considerable portion of the ganglion lies anterior to the eyes (Fig. 7) but the right and left sides of the nervous system remain united farther posteriorly than in the normal (Figs. 5 and 9). In the teratomorphic forms the eye lies dorsal to the extreme anterior portion of the ganglion and the two cords do not become separated for a considerable distance posterior to it.

In the development of the abnormal forms the eye undoubtedly arises in connection with the central nervous system as it does in the normal animals. The position and number of the eyes must be determined primarily by the condition of the nervous system, though other factors may play some part. Apparently the median regions of the nervous system are more or less reduced or fail to develop in the abnormal forms and the lateral regions consequently lie nearer together so that the eyes appear near or in the median line. The approximation and fusion of the auricles is also evidently due to the reduction or absence of the median region of the head and this condition is undoubtedly closely connected in one way or another with the condition of the ganglia. There can be no doubt that the condition of the nervous system is the most important factor in determining the characteristic features of the teratophthalmic and teratomorphic heads.

One of the most interesting points in connection with the whole series of forms is the fact that in the teratomorphic forms the whole length of the regenerated nervous system is abnormal (Figs. 13 and 14, Fig. 26, Fig. 30). Not until the level of the old tissue is reached do the two cords appear in their usual relations and even there they are commonly nearer together than in normal animals (Figs. 15, 22, 27, 31). This fact suggests that the development of the regenerated portion of the nervous system is in large measure independent of the already existing portion. If the development took place in the anterior direction from the cut ends of the nerve cords in the old tissue, it is difficult to understand how such structures as those shown in Figs. 13 and 14, 26 and 30 could arise near the old tissue. But if the development of the regenerated part takes place independently of the old part, the continuation of the abnormal structure back to the level of the preëxisting portion constitutes a less difficult problem.

According to recently published work of the senior author (Child, '11*d*) the formation of a new whole from a headless piece of *Planaria* consists essentially in the formation first of all of a new head region which then reorganizes the parts posterior to it through correlation. The structure of the regenerated portion of the nervous system in the teratomorphic forms certainly offers



more support to this conclusion than to that view which maintains that the regenerating nervous system grows out anteriorly from the cut ends of the old nerve cords. Apparently in these cases a new central nervous system develops and is abnormal from the beginning, but as its differentiation extends posteriorly it meets the old nerve cords and unites with them. In this way it is easy to account for the relatively sudden change in the structure of the nervous system as we follow it posteriorly from the new into the old tissue in some of the teratomorphic forms (Figs. 14 and 15, 26 and 27, 30 and 31). But even the anterior regions of the old nerve cords undergo reorganization to a greater or less extent under the influence of the new region anterior to them. In Figs. 15, 27 and 31 they are nearer together and connected by larger commissures than they were originally when they formed a part of the posterior region of the first zoöid.

The structure of the nervous system in the posterior part of the regenerated region in such cases as Fig. 14 and Fig. 30 suggests a breaking up into separate nerves, but posterior to the levels of these sections where the developing portion meets the old cords there is a return to something approaching normal structure. It is possible that if the old cords were not present in such cases the new nervous system would extend posteriorly as a considerable number of separated cords or nerves instead of in the form characteristic of normal animals.

It was pointed out in Section I. that the teratophthalmic and teratomorphic forms can be produced experimentally by decreasing the rate of the dynamic processes in the piece below a certain rate necessary for the production of normal animals which is itself not constant but dependent upon various conditions. These abnormal forms then represent planarian morphogenesis corresponding to certain rates of reaction below the "normal" rate for the existing conditions. The fact that changes which are primarily quantitative give rise to such differences in structure as those recorded is important. As the rate of reaction decreases we see certain parts, *e. g.*, the preocular region of the head, decreasing in relative size and finally disappearing and in the nervous system the bilateral structure of the ganglia becomes less and less distinct in consequence of the reduction and

disappearance of the median regions. Apparently we are justified in concluding that the reduction and disappearance of certain parts as the rate of reaction decreases is due one of two alternatives: first, the reduced or absent part may represent a relatively low rate of reaction in the normal animal and under the experimental conditions the rate of the reaction which is essential for its formation approaches or falls below what may be called the morphogenic threshold, *i. e.*, it does not produce the characteristic morphological effect. Second, a part may be reduced or disappear under conditions which decrease the rate of reaction, not because the reaction concerned in its formation is directly affected by the experimental conditions, but because its formation depends upon correlation with some other part which is thus affected. It is probable, for example, that the condition of the central nervous system in the abnormal forms is largely, at least in the cephalic ganglia, a direct effect of the experimental conditions, while the position, number and presence or absence of the eyes and the degree of development of the preocular region are to a considerable extent correlative effects.

But however we may account for the results it is a demonstrated fact that the reduction and disappearance of parts of so "essential" an organ as the central nervous system can be brought about experimentally by quantitative changes in external or internal conditions. No absence of chromosomes or determinants and no germinal variation is necessary for the production of these abnormal forms, but only a decrease in the rate of the dynamic processes in the piece, together with the necessary correlative effects of such a decrease.

It is impossible to leave the subject without some reference to the "cyclopean" fish embryos which Stockard ('07, '09, '10) has recently produced by means of magnesium chloride and alcohol. The resemblance between these forms and the teratophthalmic and teratomorphic forms of *Planaria* is striking. In both cases organs which are normally bilaterally symmetrical in position show various degrees of approach and in the extreme types a single median organ develops in place of the two. Anophthalmic forms also occur in *Planaria* and under extreme experimental conditions completely headless forms also appear.

Moreover, in *Planaria* the auricles, like the eyes, show various degrees of approximation and fusion and in the present paper it has been shown that similar conditions appear in the cephalic ganglia themselves. In *Planaria* these monstrous forms can be produced, not merely by anesthetics, but by a variety of conditions the essential effect of which is a decrease in the rate of the reactions in the living system. It seems probable that Stockard's cyclopean embryos and the other intermediate forms between these and the normal animals are the result of a decrease in the rate of reaction rather than of any specific anesthetic effect of either magnesium salts or alcohol. Moreover, the double or partially double heads which Stockard obtained in some cases are also readily accounted for on a quantitative basis: a decreased rate of reaction means decreased correlation and this condition favors physiological isolation of parts and reproduction, as the senior author of the present paper has shown elsewhere (Child, '11f).

The problem of the relation between morphogenesis and the rate of reaction in organisms is one of great importance, but it has received comparatively little attention. Current hypotheses of development and inheritance scarcely consider the possibility of altering the characteristic morphological features of the organism by changes in the rate of reaction, but of the fact there can be no doubt.

#### VI. SUMMARY.

1. The teratophthalmic and teratomorphic forms of *Planaria dorotocephala* can be produced experimentally by decreasing the rate of the dynamic processes in the isolated pieces below a certain variable level which is necessary for the production of normal forms.

2. In these forms the cephalic region of the nervous system differs more or less widely from that of normal animals. The two ganglionic masses are always less completely separated than in the normal animals and often only a single ganglion develops. In the teratomorphic forms the ganglia are more abnormal than in the teratophthalmic forms.

3. In the normal animals the cephalic ganglia extend a considerable distance anterior to the eyes and the two separate

nerve cords arise near the level of the auricles. In the teratophthalmic forms with partially fused eyes the eyes lie nearer the anterior end of the ganglia and the right and left portions are not separated at the level of the auricles. The eyes of the teratomorphic forms are situated at the extreme anterior end of the ganglionic mass.

4. The abnormal structure of the nervous system in the teratophthalmic and teratomorphic forms continues posteriorly through the regenerated anterior end to the level of the old tissue and even the nerve cords in the old tissue may be more or less different from the normal. In some teratomorphic forms the regenerated nervous tissue apparently begins to break up into separate nerves a short distance posterior to the eyes, but resumes the form of two nerve cords in the old tissue.

5. In the normal animal the optic pigment cups open laterally and the same is true for the teratophthalmic forms with partially fused eyes. In the teratomorphic forms the cup opens anteriorly or antero-ventrally and in some cases more or less to one side. The single median eye may be connected by two nerves with right or left portions of the ganglionic mass, or by a single nerve with either one, or the optic nerve may arise from the median region of the ganglion. The eyes are also farther from the dorsal surface in the teratomorphic than in the normal forms and are sometimes more or less completely imbedded in the ganglionic mass.

HULL ZOÖLOGICAL LABORATORY,  
UNIVERSITY OF CHICAGO,  
October, 1911.

#### REFERENCES.

Child, C. M.

- '11a Studies on the Dynamics of Morphogenesis and Inheritance in Experimental Reproduction. I. The Axial Gradient in *Planaria dorocephala* as a Limiting Factor in Regulation. *Journ. Exp. Zool.*, Vol. X., No. 3, 1911.
- '11b A Study of Senescence and Rejuvenescence Based on Experiments with *Planaria dorocephala*. *Arch. f. Entwickelungsmech.*, Bd. XXXI., H 4, 1911.
- '11c Experimental Control of Morphogenesis in the Regulation of *Planaria*. *Biol. Bull.*, Vol. XX., No. 6, 1911.
- '11d Studies on the Dynamics, etc. II. Physiological Dominance of Anterior over Posterior Regions in the Regulation of *Planaria dorocephala*. *Journ. Exp. Zool.*, Vol. XI., No. 3, 1911.

- '11e Studies on the Dynamics, etc. III. The Formation of New Zoöids in Planaria and other Forms. Journ. Exp. Zoöl., Vol. XI., No. 3, 1911.
- '11f Die physiologische Isolation von Teilen des Organismus. Vortr. u. Aufs. ü. Entwicklungsmech., H. XI., 1911.

**Stockard, C. R.**

- '07 The Artificial Production of a Single Median Cyclopean Eye in the Fish Embryo by Means of Sea Water Solutions of Magnesium Chloride. Arch. f. Entwicklungsmech., Bd. XXIII., H. 2, 1907.
- '09 The Development of Artificially Produced Cyclopean Fish — "The Magnesium Embryo." Journ. Exp. Zoöl., Vol. VI., No. 2, 1909.
- '10 The Influence of Alcohol and other Anesthetics on Embryonic Development. Am. Journ. Anat., Vol. X., No. 3, 1910.